

Author:

Beth D. Darnall, PhD

Affiliation:

From the Department of Anesthesiology and Perioperative Medicine, Oregon Health and Science University, Portland, Oregon.

Correspondence:

All correspondence and requests for reprints should be addressed to Beth Darnall, PhD, Department of Anesthesiology and Perioperative Medicine, Oregon Health and Science University, 3181 Sam Jackson Park Road; UHN-2, Portland, OR 97239.

Disclosures:

Supported by a grant from the Office of Research on Women's Health (BIRCWH) 2K12HD043488-06.

0894-9115/09/8801-0078/0
American Journal of Physical Medicine & Rehabilitation
Copyright © 2008 by Lippincott Williams & Wilkins

DOI: 10.1097/PHM.0b013e318191105b

Amputee

CASE REPORT

Self-Delivered Home-Based Mirror Therapy for Lower Limb Phantom Pain

ABSTRACT

Darnall BD: Self-delivered home-based mirror therapy for lower limb phantom pain. *Am J Phys Med Rehabil* 2009;88:78–81.

Home-based patient-delivered mirror therapy is a promising approach in the treatment of phantom limb pain. Previous studies and case reports of mirror therapy have used a therapist-guided, structured protocol of exercises. No case report has described treatment for either upper or lower limb phantom pain by using home-based patient-delivered mirror therapy. The success of this case demonstrates that home-based patient-delivered mirror therapy may be an efficacious, low-cost treatment option that would eliminate many traditional barriers to care.

Key Words: Mirror Therapy, Amputation, Phantom Limb Pain, Lower Limb

Each year in the United States, ~158,000 persons undergo an amputation.¹ Incidence of acquired amputation is increasing likely because of military conflict injuries and the increasing prevalence of diabetes-related peripheral vascular disease. Prevalence of acquired amputation varies by region, sex, and type of amputation. For first major amputations, United States data from 1992 to 1997 range from almost 1 per 10,000 women in Alabama to 4.4 per 10,000 men in the Navajo Nation.² A national survey of community dwelling persons with limb loss ($n = 914$) reported a prevalence ratio of 8:1 for lower limb loss compared with upper limb loss.³ Phantom pain is a commonly experienced comorbid condition. Sixty-four percent of persons with limb loss reported experiencing phantom limb pain that was rated at least "bothersome" in nature. Prevalence of "severely bothersome" phantom limb pain was 21%.³ Eighty-seven percent of this limb loss sample was >2 yrs after amputation, and 42.3% was >6 yrs after amputation. These data speak to the chronicity of phantom limb pain, as well as the lack of efficacious and widely available treatments.

Ramachandran and Rogers-Ramachandran⁴ have described the use of mirror therapy to treat phantom limb pain. Persons with an amputated limb use either a mirror or a mirror box to reflect an image of the intact limb; this provides the visual illusion that two intact limbs exist. Despite a greater prevalence of lower limb amputation, mirror therapy for phantom limb pain has largely focused on treatment for upper limb loss, and its efficacy in this population has been demonstrated.⁴ It is hypothesized that the mechanism

supporting the efficacy of mirror therapy for upper limb phantom pain is cortical restructuring.⁵ Two studies examining the efficacy of mirror therapy for lower limb phantom pain were found. The first was a randomized, controlled trial for lower limb phantom pain that compared treatment effects between a group that viewed a computerized image of an intact "virtual" limb to a group that received traditional mirror therapy.⁶ Persons in the virtual-limb mirror condition did not experience the expected decreases in phantom limb pain associated with traditional mirror therapy. The second report of lower limb mirror therapy involved randomization of 18 participants into three groups: the mirror group received traditional mirror therapy; the sham mirror group viewed a covered mirror and attempted to move both their intact and amputated limbs in front of the covered mirror; and the mental visualization group closed their eyes and imagined moving their amputated limb.⁷ The persons in the mirror group had direct supervision while performing the mirror exercises for 15 mins daily. Every person in the mirror group (100%) evidenced significant improvement in 4 wks (24-mm median decrease on the visual-analog scale) compared with only one person in the sham mirror group (17%) and three people in the visualization group (50%) reporting similar pain decreases. Furthermore, more than half of the participants in the nonmirror groups reported worsening pain after their treatments. Four weeks after crossover to the mirror therapy group, 89% of participants formerly from the sham mirror and mental visualization groups reported significant phantom pain reduction. Finally, successful treatment for lower limb phantom pain using a structured, clinical approach to exercising the phantom limb has also been described.^{8,9} No case report has described treatment for either upper or lower limb phantom pain by using home-based, patient-delivered mirror therapy.

CASE DESCRIPTION

The patient gave consent to publish a description of his case, but his name was changed to maintain confidentiality. "Jonathan" is a 35-yr-old man with acquired above-knee amputation of the left lower limb. He suffered limb mangling and subsequent amputation after being struck by a motor vehicle as a pedestrian in 2006. He began experiencing phantom pain immediately after surgery; he described it as having a "sharp, shooting" quality that felt as if the phantom foot had fallen asleep. Intensity varied from none to severe. His postoperative pain was managed with hydrocodone-acetaminophen (Vicodin 5/500 every 4–6 hrs as needed). Physical therapy was initiated about

1 mo after surgery. He was being treated for major depression that predated his amputation.

Jonathan was referred to a tertiary academic chronic pain clinic in September 2006 for medical evaluation. He was prescribed daily Effexor XR 150 mg for pain and depression. He rated his pain as 6/10. He was taking only Vicodin for pain. He was treated by an inhouse pain psychologist and had a modest response to a standard pain management protocol that included relaxation techniques (diaphragmatic breathing and progressive muscle relaxation). He returned to work on a part-time basis in the fall. Physical therapy was concluded in December 2006, and he had begun a home exercise program that largely involved weight training. Despite these treatments, his pain worsened in January 2007. He developed a rash to the subtherapeutic dose of pregabalin 300 mg that was tried on him; this medication was discontinued. Gabapentin (Neurontin) 600 mg thrice a day and oxcarbazepine (Trileptal 600 mg twice a day) were tried. Financial limitations precluded optimal refitting of his prosthesis, and this contributed to ongoing residual limb pain caused by friction generated by the ill-fitting device during ambulation.

He was referred to a second inhouse pain psychologist for specialized treatment for phantom limb pain in February 2007. His phantom pain was rated 4/10. He was taking 3–4 Vicodin daily for pain and reported feeling undesirable cognitive "fuzziness" from the medication. At the time of evaluation, he had been working full time for 2 mos; he was fearful of the negative impact opioid medication would have on his cognitive functioning. In terms of other medications, he was still taking gabapentin 1200 mg and oxcarbazepine 600 mg without benefit. He noted that mentally flexing his phantom limb would gain him some temporary relief; he initiated this imagery practice on his own and had been practicing for 20 mins at a time for the past 3 mos.

Jonathan was seen for a total of five 60-min psychology sessions during 3 mos for home delivered mirror therapy. The following list outlines his progress with treatment.

1. I discussed the mirror therapy technique with him and provided him with educational material describing its application and efficacy for upper limb amputees. He expressed interest in trying this form of therapy with the understanding that it was experimental and not well described for lower limb amputees. We discussed the goal of using the mirror technique while mentally engaging the phantom limb; he was not given any structured exercise protocol. He was given a CD of guided diaphragmatic

breathing and progressive muscle relaxation (25 mins), and I encouraged him to practice the relaxation skills several times daily, independent of his mirror therapy. Jonathan was already familiar with these relaxation skills from his treatment with his previous pain psychologist.

2. He purchased a simple full-length mirror (4 ft long and 1.5 ft wide) from a discount store (approximate cost \$10). He placed the mirror on its edge, longitudinally, against a coffee table in his living room and positioned his intact limb in front of the mirror. The mirror image of his intact limb provided the visual illusion that he was viewing two intact limbs (Fig. 1). He followed a largely unstructured protocol designed by himself. During his mirror sessions, he exercised his intact foot and watched the movements in the mirror. He tended to include the following movements: flexing his foot up and down at the ankle, rotating his ankle in circles, touching his big toe in the mirror, raising and lowering his leg from the hip, and bending his leg at the knee. He self-delivered the mirror technique at home three times a week for 20–30 mins per session. He noted that his ongoing practice of the diaphragmatic breathing decreased the tingling sensations and calmed his daily general anxiety. Because he was able to practice the mirror therapy at home only, at work he would visualize flexing his phantom limb; doing so would allow him to “exercise” the phantom limb at work and increase blood flow to the residual limb. He was encouraged to

continue with relaxation exercises and with his mirror therapy practice.

3. He reported having increased the frequency of self-delivered home-based mirror therapy in the past 2 wks to 30 mins daily. He experienced no aversive sensations or memories while practicing the mirror therapy. Rather, he reported experiencing decreased pain, increased control, and a sense of enjoyment from the practice. In the 3 days before this follow-up session, he needed no Vicodin for pain control. He began tapering off his gabapentin.
4. He noted a direct correlation between the frequency of self-delivered mirror therapy practice and pain intensity. After practicing mirror therapy 20 mins daily for 1 mo, he reported that his phantom limb pain was resolved (0/10). He continued to have some residual limb (stump) pain (3/10) that improved with exercise.
5. Three months after the initial evaluation, his phantom limb pain was resolved, and nerve pain was very well managed. He reported his mood was improved and anxiety was low; both were assessed via clinical interview. He reported feeling confident that he could self-manage his pain symptoms. He was using Vicodin about once weekly as needed. He noted that if he missed his regular practice of mirror therapy, the phantom pain returned within 1–2 days. He was able to control any recurrence of pain by resuming regular mirror practice. He indicated that consistent mirror practice was important for controlling his phantom pain and for minimizing his reliance on pain medication.

Table 1 reflects the percent change in Jonathan's pain and pain-related interference on relevant life domains from pretreatment to posttreatment, measured with the Brief Pain Inventory, a self-report measure validated for use with noncancer pain.¹⁰ Results show complete resolution of adverse symptoms (100% change) related to pain, mood, work, and sex. Investigators commonly use a 50% change from baseline to post-treatment as the criterion for treatment success. Jonathan's improvements in all domains were sustained 4 mos post treatment.

DISCUSSION

Jonathan's case elucidates several important points. Although he was receiving multidisciplinary care for his phantom limb pain (pain medicine, physical therapy, and psychology), his results with standard care were unsatisfactory. The resolution of his phantom limb pain occurred after the

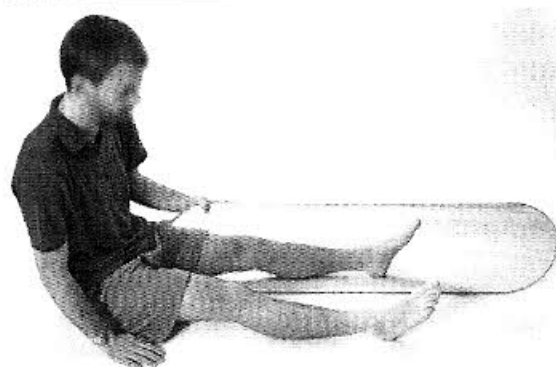


FIGURE 1 A model demonstration of the mirror technique used by Jonathan. He practiced self-delivered home-based mirror therapy by placing a long mirror in front of his residual limb to create the image of two intact limbs.

TABLE 1 Percent change from baseline to post-treatment for pain and other life domains. Pain was assessed using a 0–10 visual analog scale. Scores for mood, work, and sex were taken from the patient's brief pain inventory and reflect the impact of pain on the designated activity (0–10)

| | Pain (0–10 VAS) | Impact of Pain on the Following Domains: | | |
|-------------------------|--------------------|--|------|------|
| | | Mood | Work | Sex |
| Baseline (February) | 4/10 | 7/10 | 2/10 | 5/10 |
| Post treatment (May) | 0/10 | 0/10 | 0/10 | 0/10 |
| % Change | 100 | 100 | 100 | 100 |

VAS, visual analog scale.

initiation of self-delivered home-based mirror therapy. His strong and enduring favorable response to the self-delivered mirror therapy above and beyond all previous treatment modalities is noteworthy. The mechanism of his response to mirror therapy is unknown but may include a combination of neural restructuring, conditioning processes, and improved self-efficacy for pain and anxiety. Although continued practice was required for sustained results, perhaps a treatment threshold can be reached in the long term, and mirror therapy can be discontinued.

This case report adds to the growing body of literature describing successful treatment of lower limb phantom pain with mirror therapy. Furthermore, this case report is unique because Jonathan's mirror therapy was self-delivered at home without the guidance of a structured exercise protocol. It is possible that other patients may benefit from simple educational brochures that describe how to self-deliver mirror therapy at home. MacLachlan et al.⁸ offer several exercises that may be useful to patients who require increased structure. However, the present case suggests that frequency and duration of practice may be variables of greater importance than following a structured protocol of exercises.

Among amputees, phantom limb pain is prevalent and efficacious treatments have been lacking. The success of this case offers preliminary evidence that fully self-delivered mirror therapy in an at-home setting can improve lower limb phantom pain. Mirror therapy may prove to be a low-cost treatment that ameliorates pain, increases patients' self-efficacy and sense of control regarding their condition, and decreases reliance on opioid medi-

cation. Self-delivered mirror therapy is likely to gain importance as increasing numbers of veterans return from conflict with an amputation. Previous data suggest persons who rate their phantom limb pain as "extremely bothersome" are at a 2.92-fold increased risk for experiencing a significant level of depressive symptoms ($P < 0.001$), compared with those with no phantom limb pain.³ Thus, accessible and efficacious treatment for phantom pain stands to provide patients with a significant improvement in overall quality of life.

ACKNOWLEDGMENTS

I acknowledge Jonathan's tenacity in overcoming significant obstacles associated with limb loss and his willingness to share his story in the hope that it will help other persons with limb loss experience similar success. I also express my gratitude to Tonya Palermo, PhD, for scientific advisement and to Kathy Gage for editorial review of the final manuscript.

REFERENCES

1. Dillingham TR, Pezzin LE, MacKenzie EJ: Limb amputation and limb deficiency: Epidemiology and recent trends in the United States. *South Med J* 2002; 95:875–83
2. Ephraim PL, Dillingham TR, Sector M, et al: Epidemiology of limb loss and congenital limb deficiency: A review of the literature. *Arch Phys Med Rehabil* 2003;84:747–61
3. Darnall BD, Ephraim P, Wegener ST, et al: Depressive symptoms and mental health service utilization among persons with limb loss: Results of a national survey. *Arch Phys Med Rehabil* 2005;86:650–8
4. Ramachandran VS, Rogers-Ramachandran D: Synaesthesia in phantom limbs induced with mirrors. *Proc Biol Sci* 1996;263:377–86
5. Flor H, Birbaumer N: Phantom limb pain: Cortical plasticity and novel therapeutic approaches. *Curr Opin Anaesthesiol* 2000;13:561–4
6. Brodie EE, Whyte A, Niven CA: Analgesia through the looking glass? A randomized controlled trial investigating the effect of viewing a 'virtual' limb upon phantom limb pain, sensation and movement. *Eur J Pain* 2007;11:428–36
7. Chan BL, Wit R, Charrow AP, et al: Mirror therapy for phantom limb pain. *N Engl J Med* 2007;357: 2206–7
8. MacLachlan M, McDonald D, Waloch J: Mirror treatment of lower limb phantom pain: A case study. *Disabil Rehabil* 2004;26:901–4
9. Brodie EE, Whyte A, Waller B: Increased motor control of a phantom leg in humans results from the visual feedback of a virtual leg. *Neurosci Lett* 2003; 341:167–9
10. Keller S, Bann CM, Dodd SL, et al: Validity of the Brief Pain Inventory for use in documenting the outcomes of patients with noncancer pain. *Clin J Pain* 2004;20:309–18